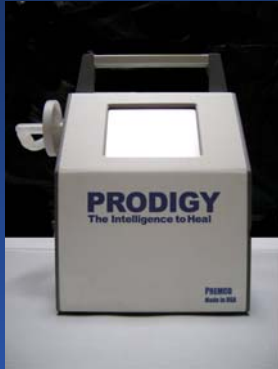



Use of Negative Pressure Wound Therapy in Treating Severe Degloving Injuries of the Foot

Ye-Ping Zhou MD, Department of Surgery, Peking University Health Sciences Center, Beijing, PRC; Michael S. Miller DO, The Wound Healing Center Terre Haute, IN



The patient is a 54 year old male who suffered a severe degloving injury to the foot. He was taken to the Peking University Health Science Center where urgent debridement was performed. The patient subsequently underwent placement of Negative Pressure Wound Therapy via the Chariker-Jeter technique using the PREMCO Prodigy. Pressures of 70mmHg were used to treat the wound. Over the next several weeks, a healthy bed of granulation tissue developed allowing for skin grafting.

